

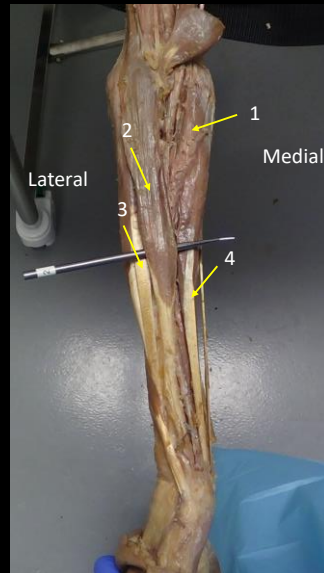
Forearm review quiz

In this review, you will see "Where am I?" on some of the slides. If you hover over the "Where am I" box, it will tell you where you are. Some slide have hints. If you need the hint hover over the box and the hint will be revealed. Make sure the finger icon is showing in order to show the text. Good luck



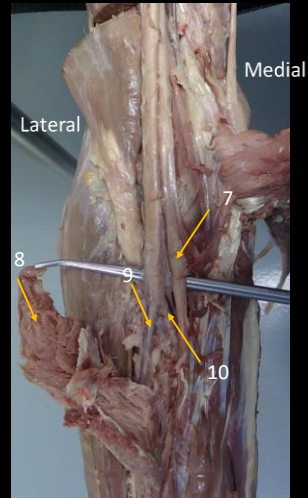
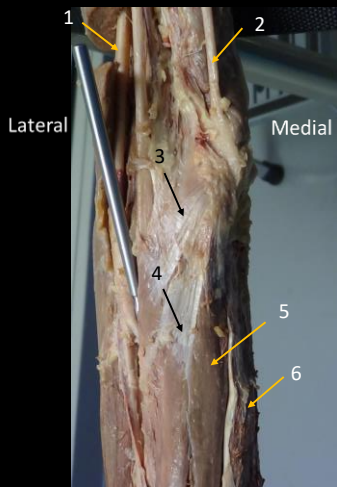
Identify the following tags

Where am I?



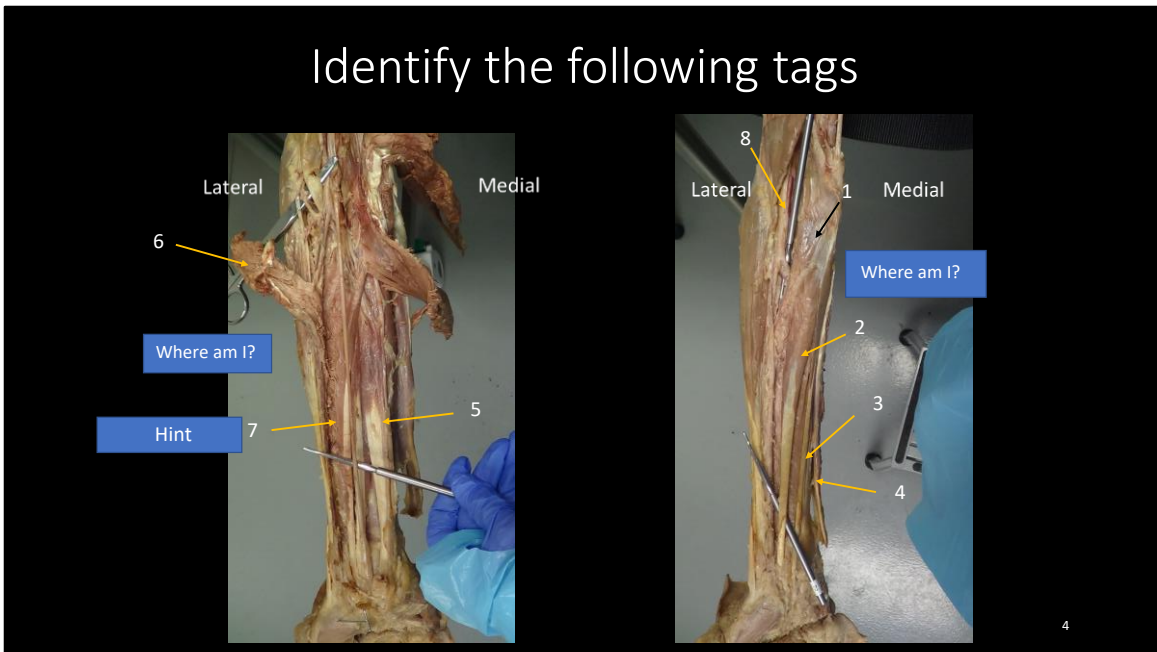
- 1 = PRONATOR TERES
- 2 = BRACHIORADIALIS
- 3 = EXTENSOR CARPI RADIALIS LONGUS
- 4 = FLEXP CARPI RADIALIS LONGUS

Identify the following tags



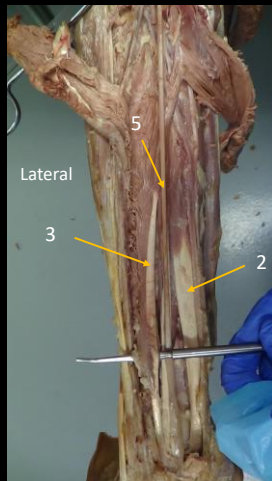
- 1 = BRACHIAL ARTERY
- 2 = ULNAR NERVE
- 3 = PRONATOR TERES
- 4 = FLEXOR CARPI RADIALIS
- 5 = PALMERIS LONGUS
- 6 = FLEXOR CARPI ULNARIS
- 7 = MEDIAL NERVE
- 8 = PRONATOR TERES
- 9 = RADIAL ARTERY
- 10 = ULNAR ARTERY

Identify the following tags

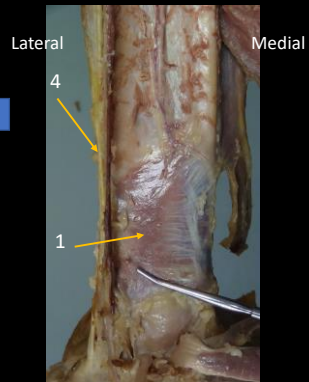


- 1 = PRONATOR TERES
- 2 = FLEXOR CARPI RADIALIS
- 3 = PALMERIS LONGUS
- 4 = FLEXOR CARPI ULNARIS
- 5 = FLEXOR DIGITORUM PROFUNDUS
- 6 = PRONATOR TERES
- 7 = FLEXOR POLLICUS LONGUS

Identify the following tags

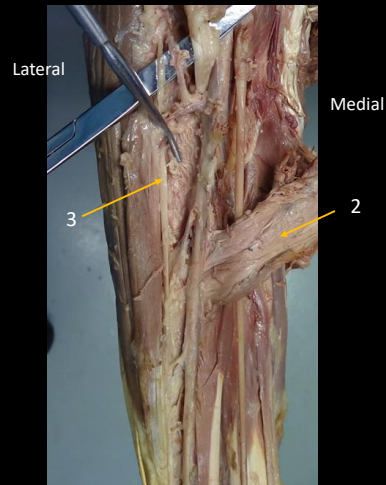
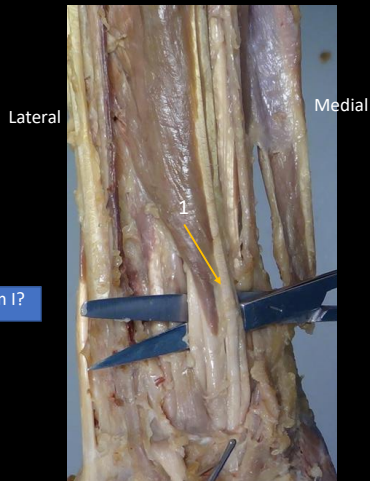


Where am I?



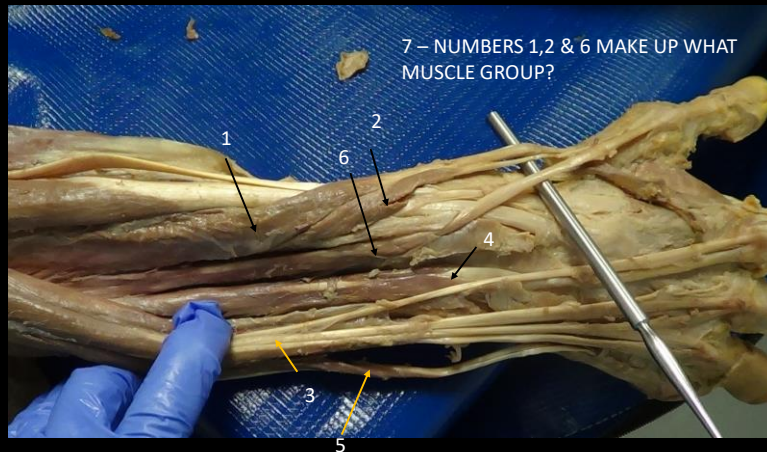- 1 = PRONATOR QUADRATUS
- 2 = FLEXOR DIGITORUM PROFUNDUS
- 3 = FLEXOR POLLICIS LONGUS
- 4 = BRACHIORADIALIS
- 5 = MEDIAN NERVE

Identify the following tags



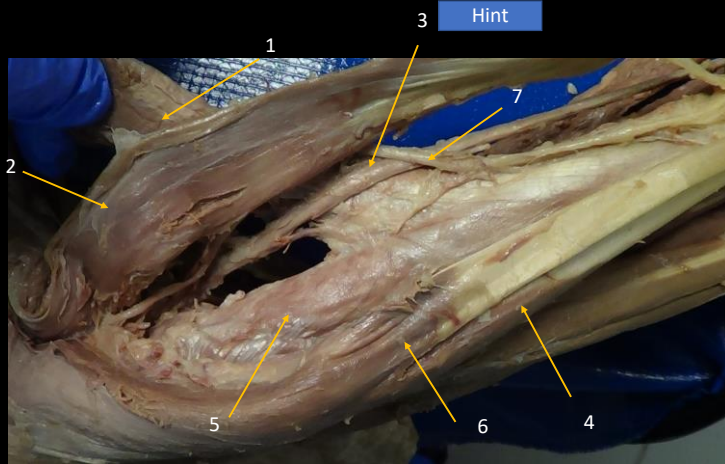
- 1 = FLEXOR DIGITORUM PROFUNDUS
- 2 = PRONATOR TERES
- 3 = DEEP BRANCH OF THE RADIAL NERVE

Identify the following tags




- 1 = ABDUCTOR POLLICUS LONGUS
- 2 = EXTENSOR POLLICUS BREVIS
- 3 = EXTENSOR COMMUNIS OR COMMON EXTENSOR
- 4 = EXTENSOR INDICIS
- 5 = EXTENSOR DIGITI MINIMI
- 6 = EXTENSOR POLLICUS LONGUS
- 7 = THESE ARE THE OUTCROPPERS

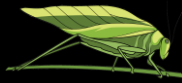Identify the following tags



- 1 = PRONATOR TERES
- 2 = BRACHIORADIALIS
- 3 = RADIAL ARTERY
- 4 = EXTENSOR CARPI RADIALIS BREVIS
- 5 = SUPINATOR
- 6 = EXTENSOR CARPI RADIALIS LONGUS
- 7 = RADIAL NERVE

THE END

Can you solve this 



9

Why did the chicken cross the road??